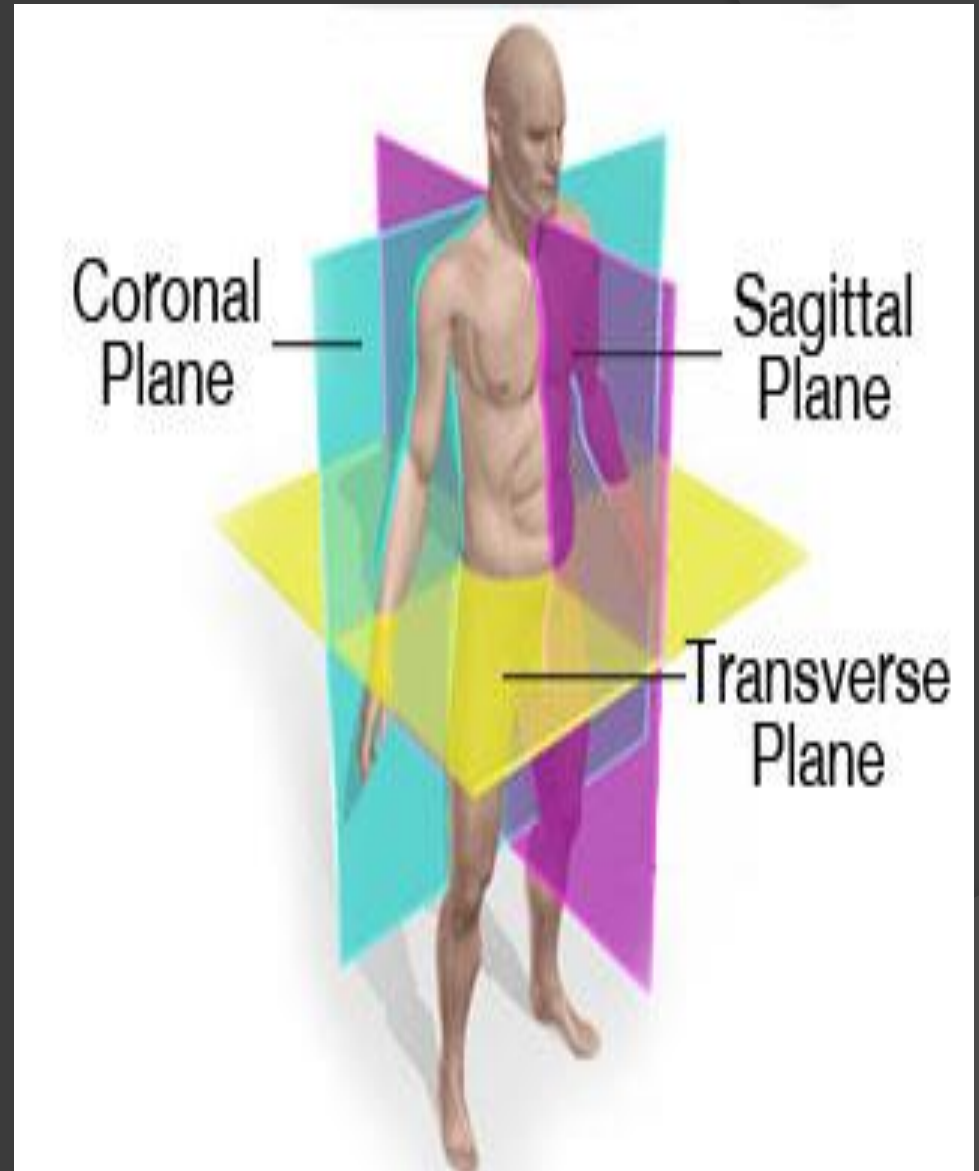


# INTRODUCTION TO ANATOMY

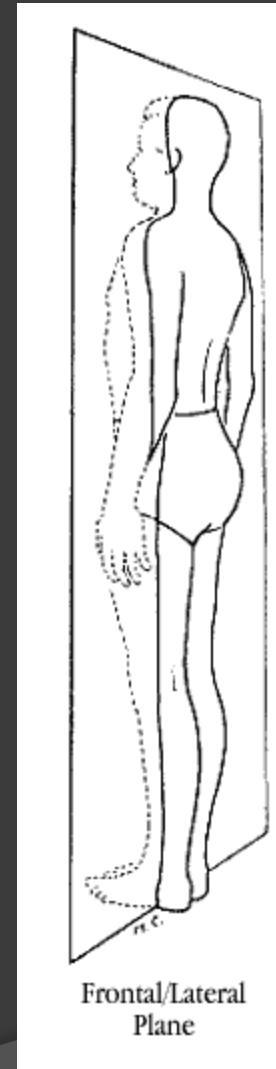
# Body Planes

- ③ 3 common planes that dissect the body
- ③ Body movements occur in a specific plane



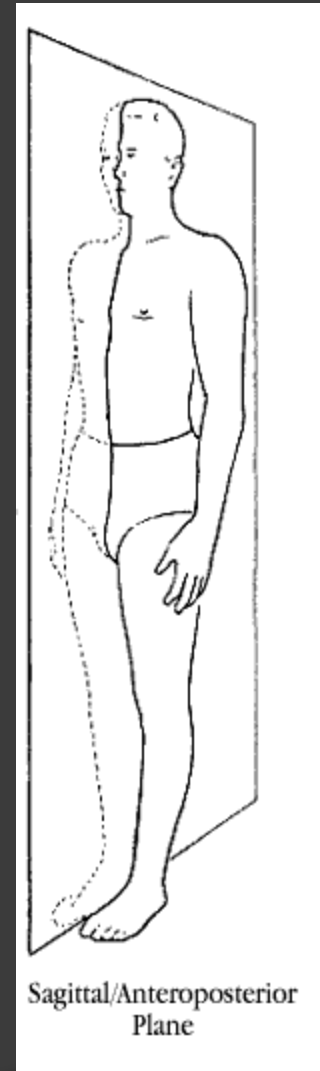
# Body Planes

- Frontal (coronal) Plane- passes vertically through the body, dividing the body into anterior and posterior sections



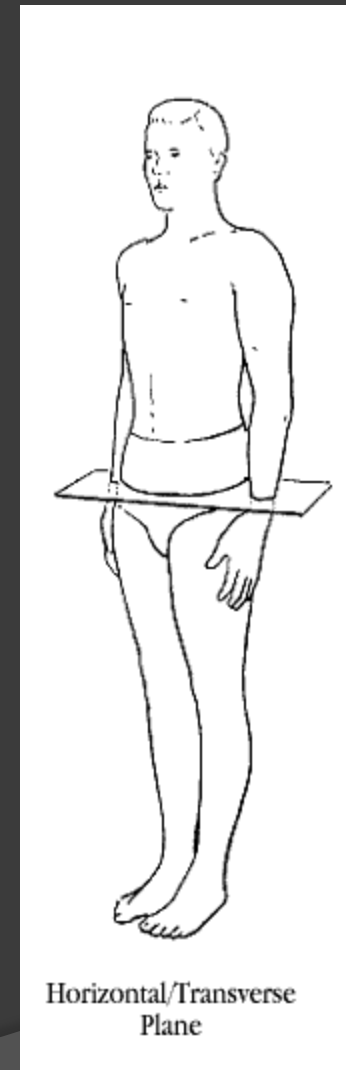
# Body Planes

- Sagittal Plane-  
passes vertically  
through the body,  
dividing the body  
into left and right  
halves



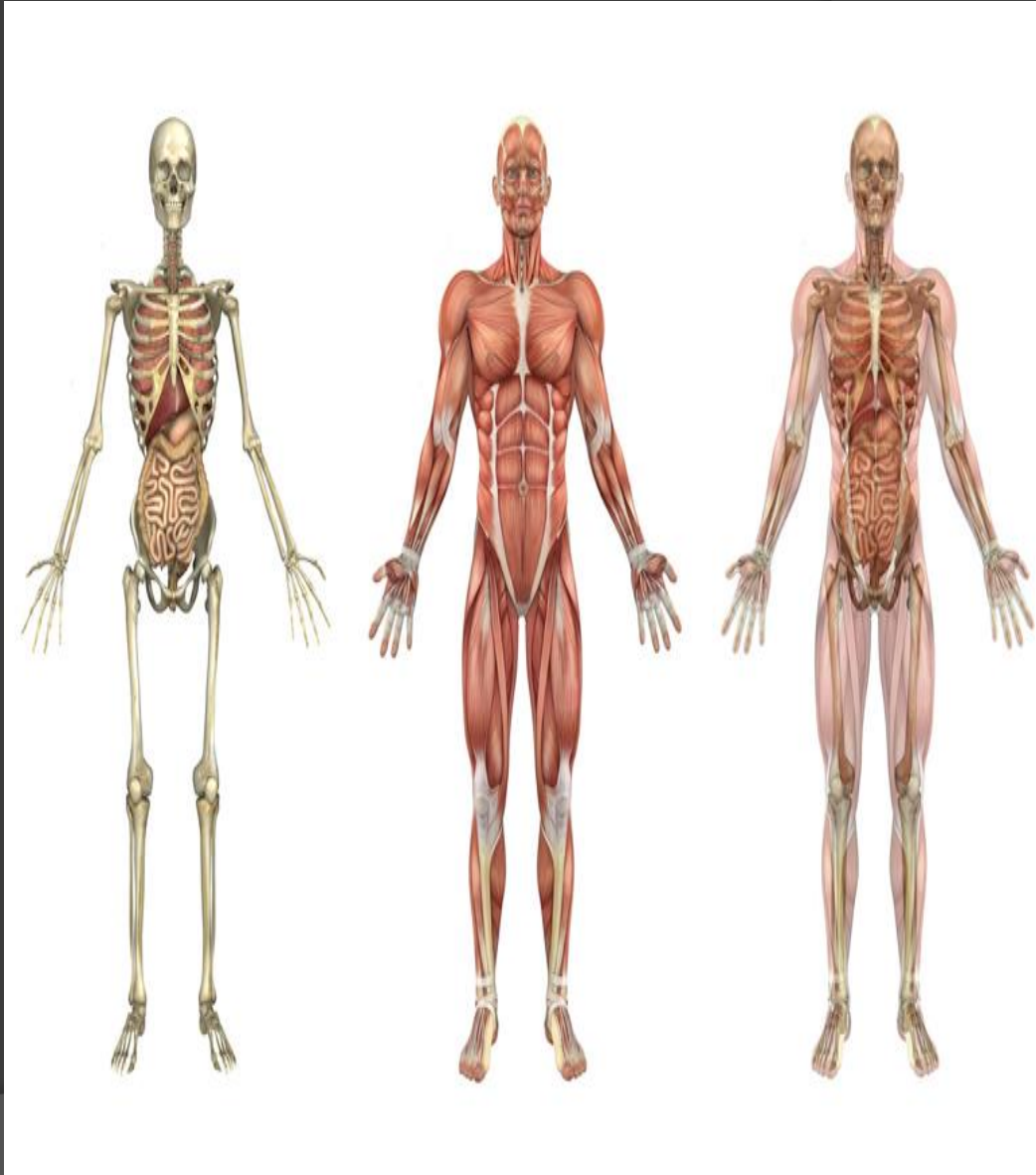
# Body Planes

- Transverse Plane- passes through the body horizontally, dividing the body into upper (superior) and lower (inferior) sections



# Anatomical Position

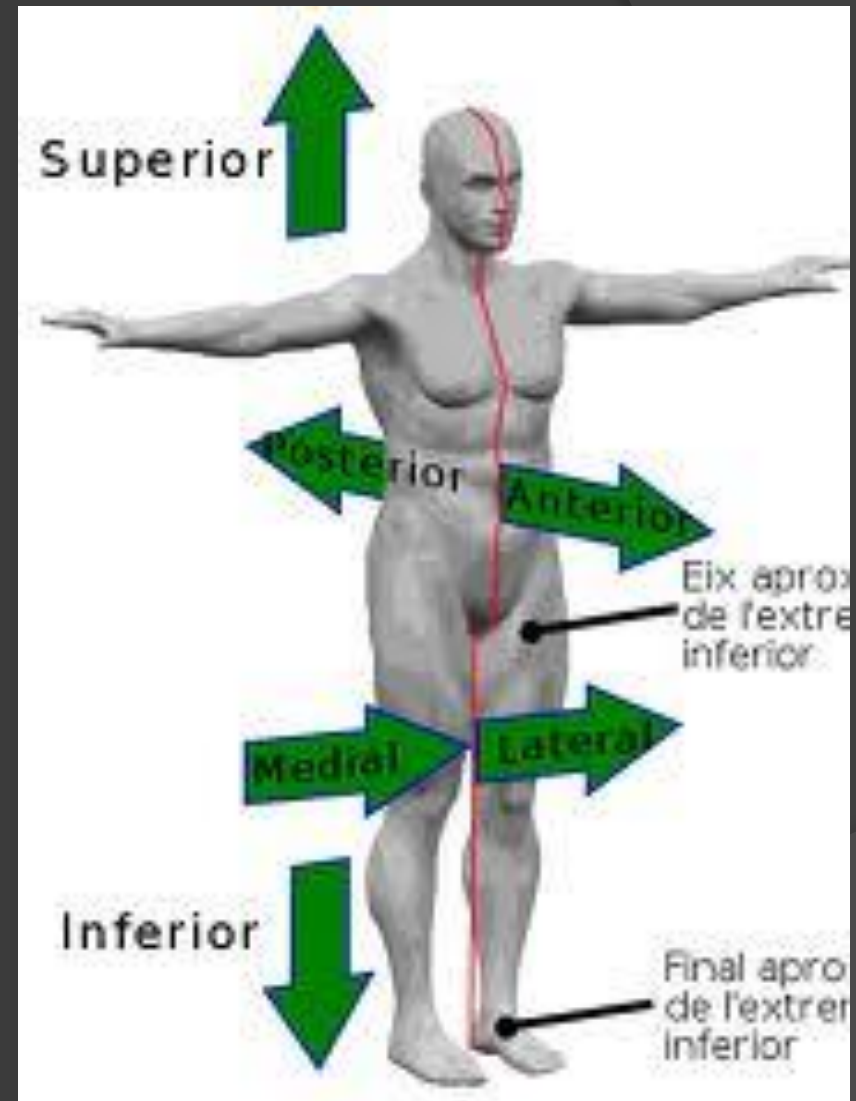
- ◉ The position the body is in for the purposes of description.
  - Face forward
  - Arms at side
  - Palms directed forward
  - Toes directed forward
  - Feet together



# Directional Terms

- Anterior- before or in front of
- Posterior- toward the rear or back

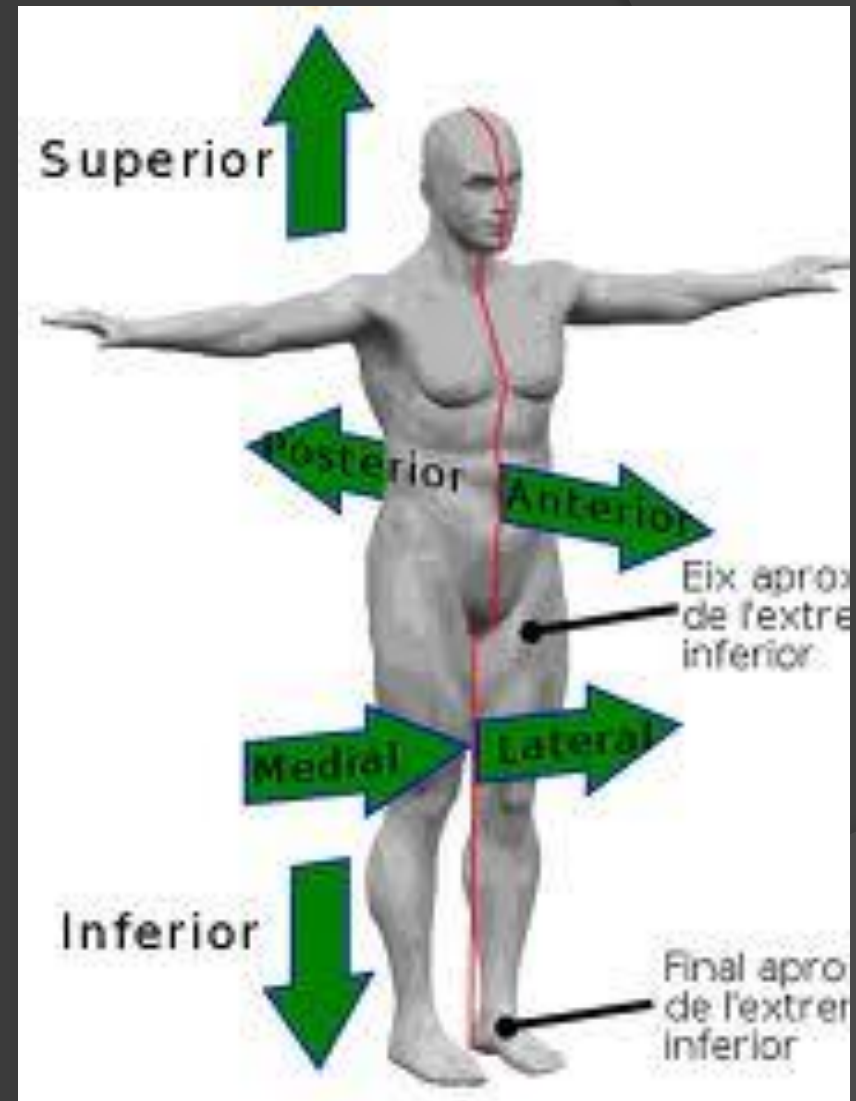
Which is more anterior, your umbilicus or your spine?



# Directional Terms

- Superior-located higher or above
- Inferior-situated under or beneath

Which is more inferior, your eyes or your mouth?

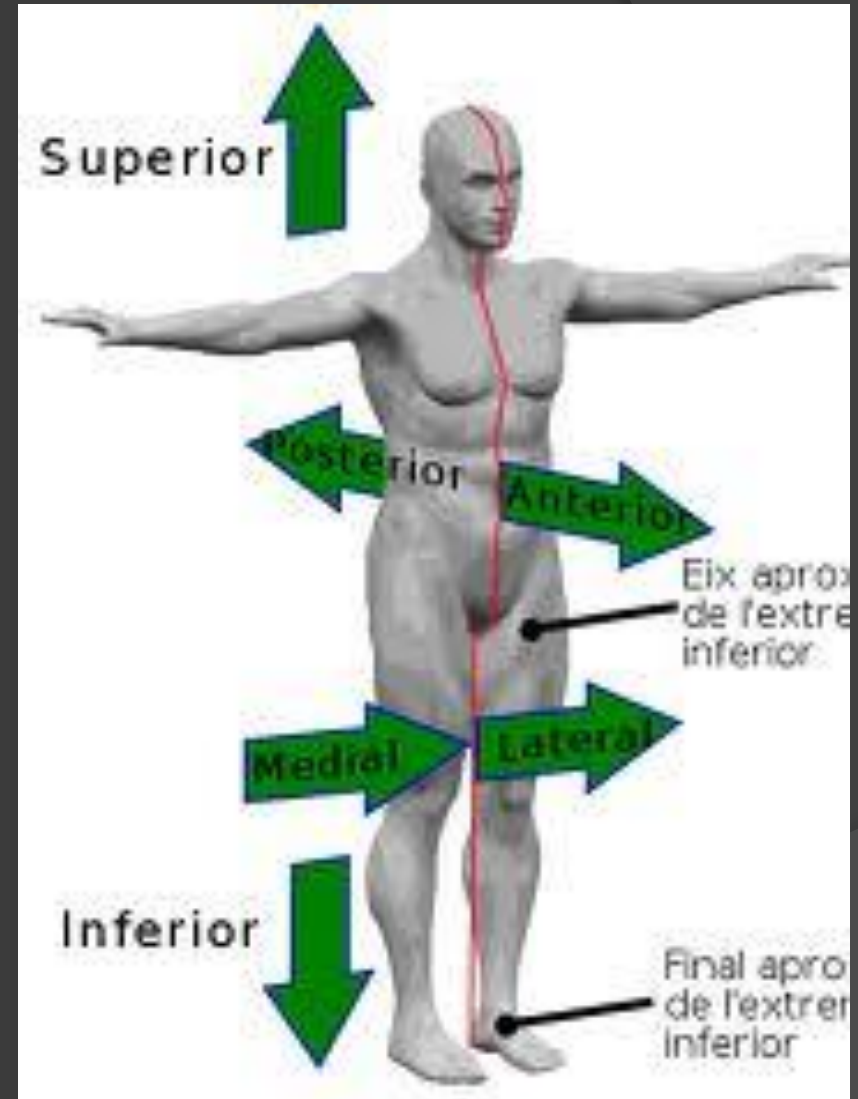




# Directional Terms

- Medial-closest to the midline of the body
- Lateral-away from the midline of the body

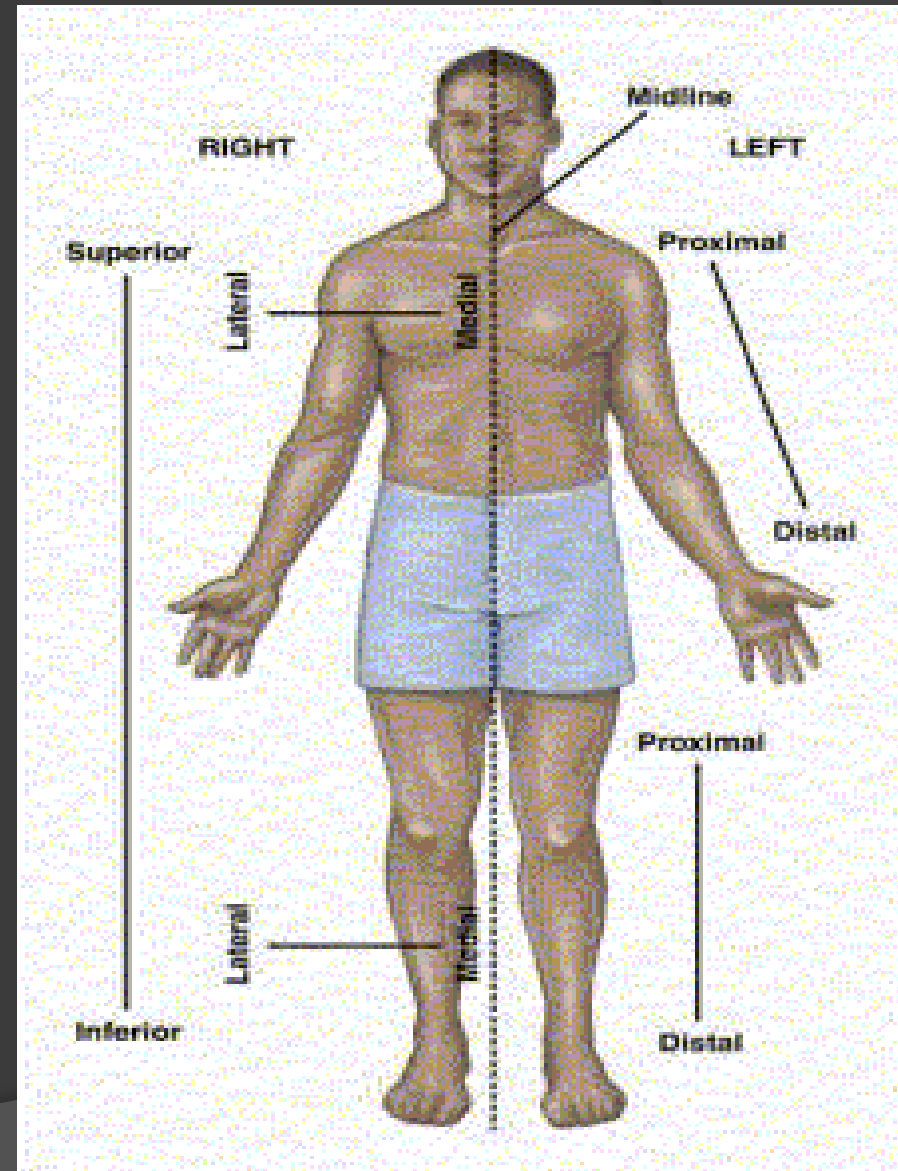
Your thumb is \_\_\_\_\_  
to your pinky finger.



# Directional Terms

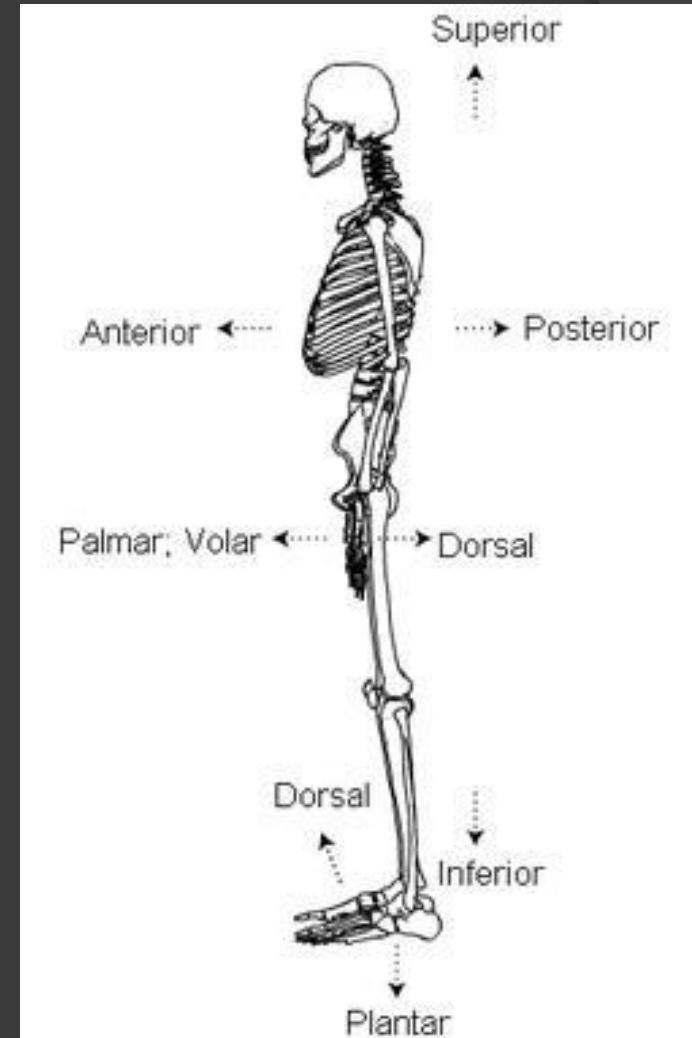
- Proximal-nearest to the midline/middle of the body
- Distal-further away from the midline/middle of the body

Your toes are more \_\_\_\_\_ than your knees.



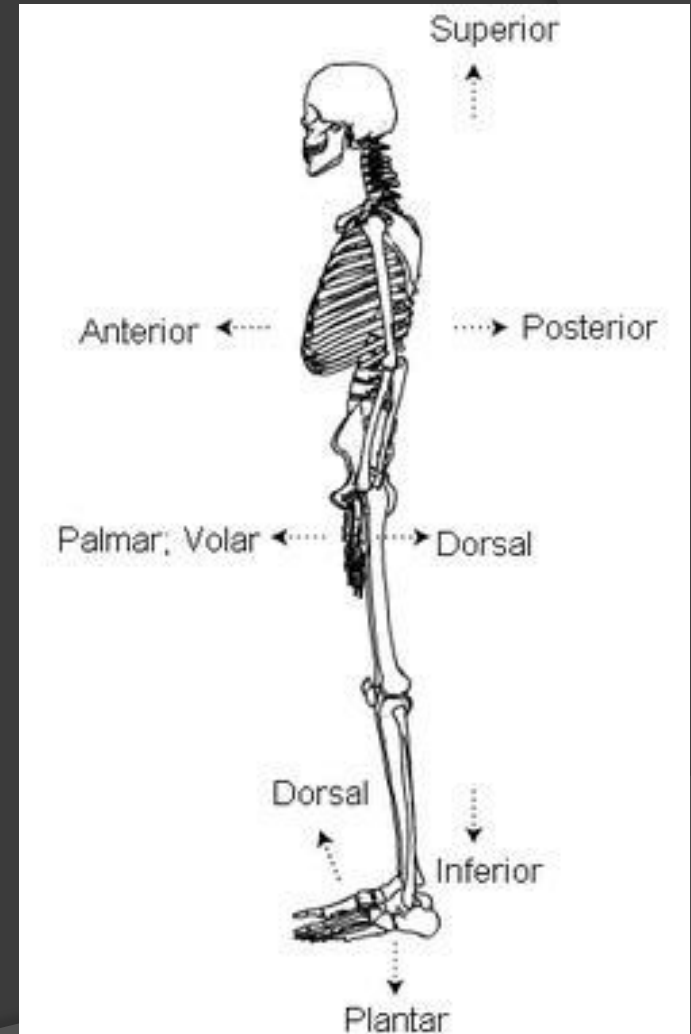
# Directional Terms

- Palmar-located in or on the palm
  - Dorsal/dorsum-the back of a body part
  - Ventral-the front; anterior
- \*often used in veterinary medicine\*



# Directional Terms

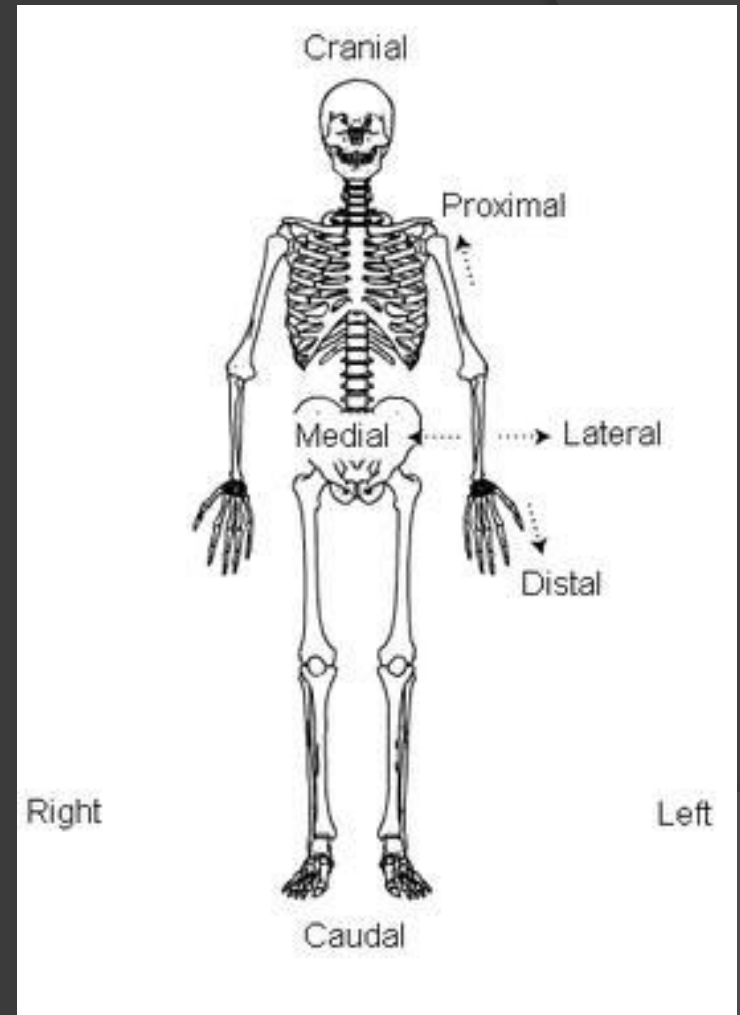
- ⦿ Dorsal-top of the foot
- ⦿ Plantar-sole of the foot



# Directional Terms

- Cranial-referring to the cranium; anterior
- Caudal-referring to the feet; posterior

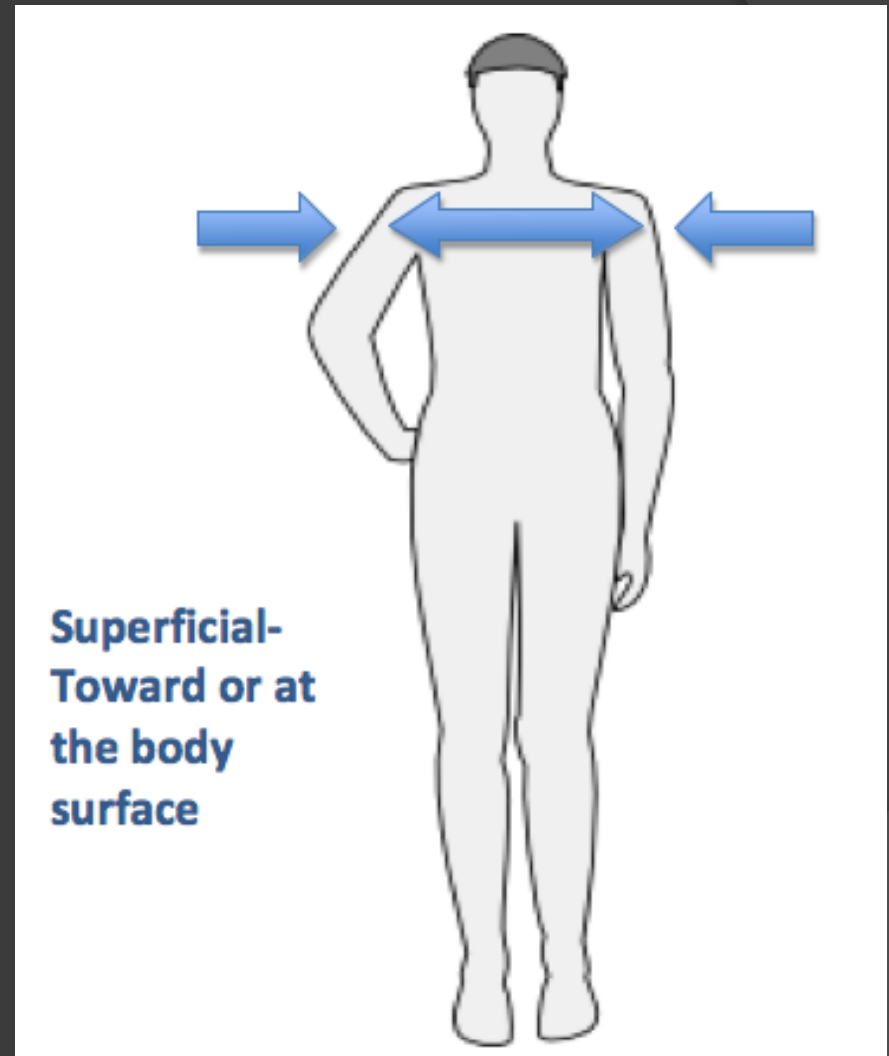
\*often used in  
veterinary medicine\*



# Directional Terms

- Superficial-closer to the surface of the body
- Deep-further away from the surface of the body

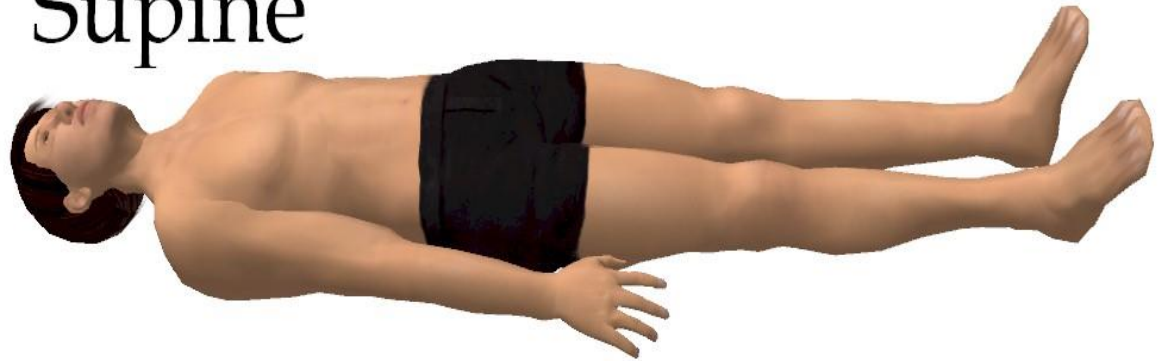The heart is \_\_\_\_\_  
than the ribs.



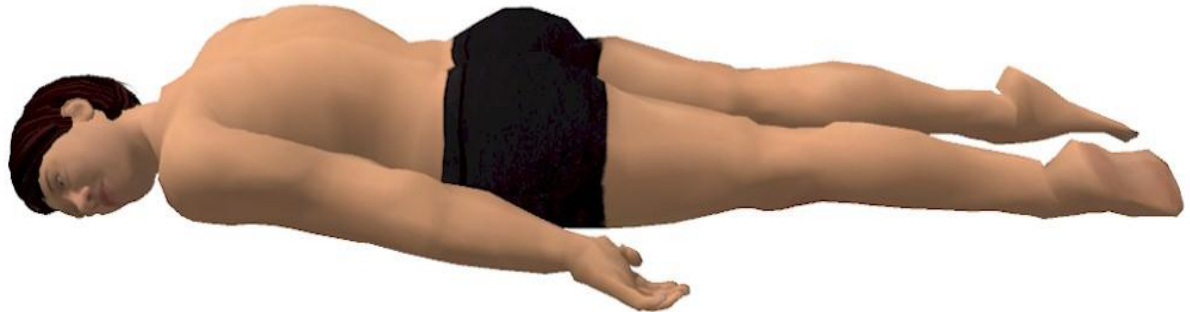# Directional Terms

- ⦿ Supine-facing upward
- ⦿ Prone-facing downward


Supine



Prone



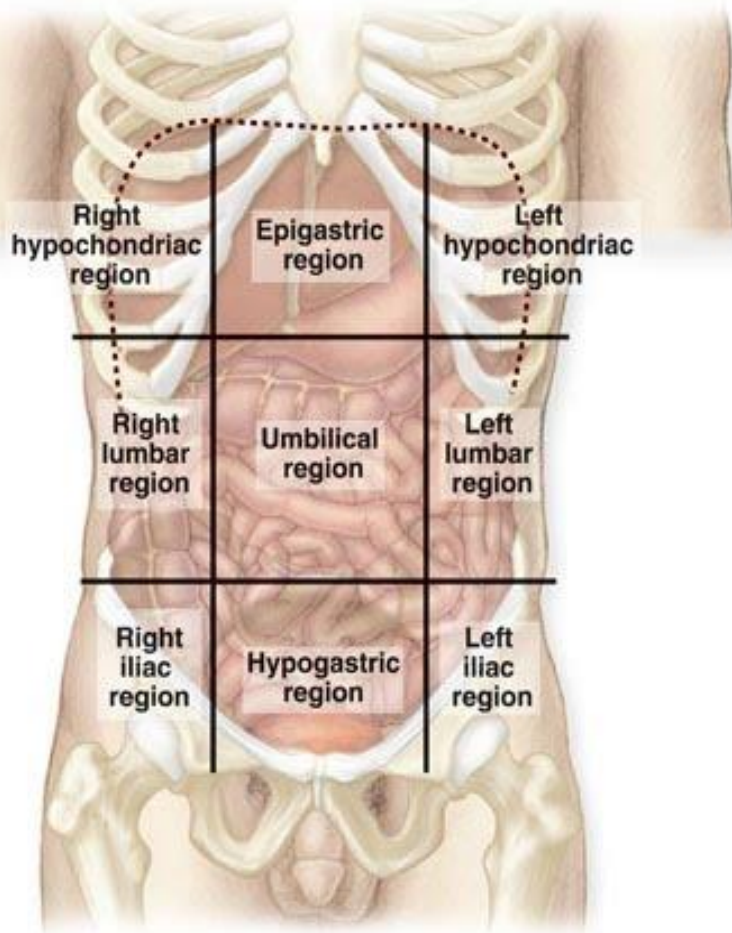
# Directional Terms



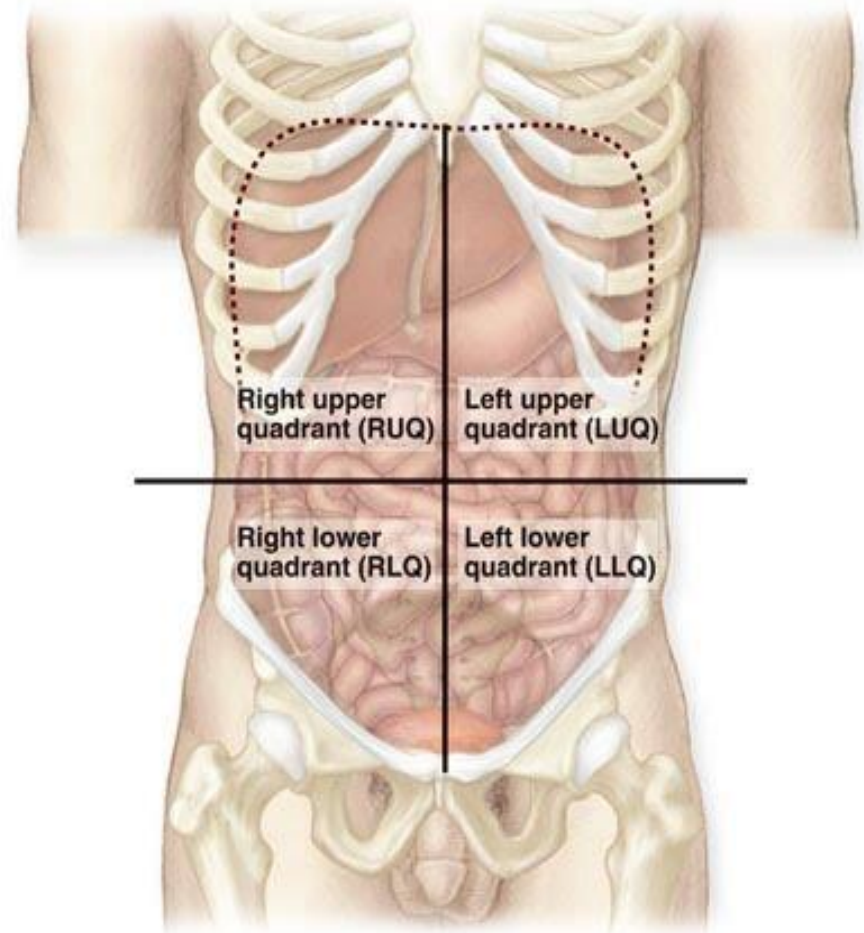


# Body Quadrants and Regions

Copyright © The McGraw-Hill Companies, Inc. Permission required for reproduction or display.

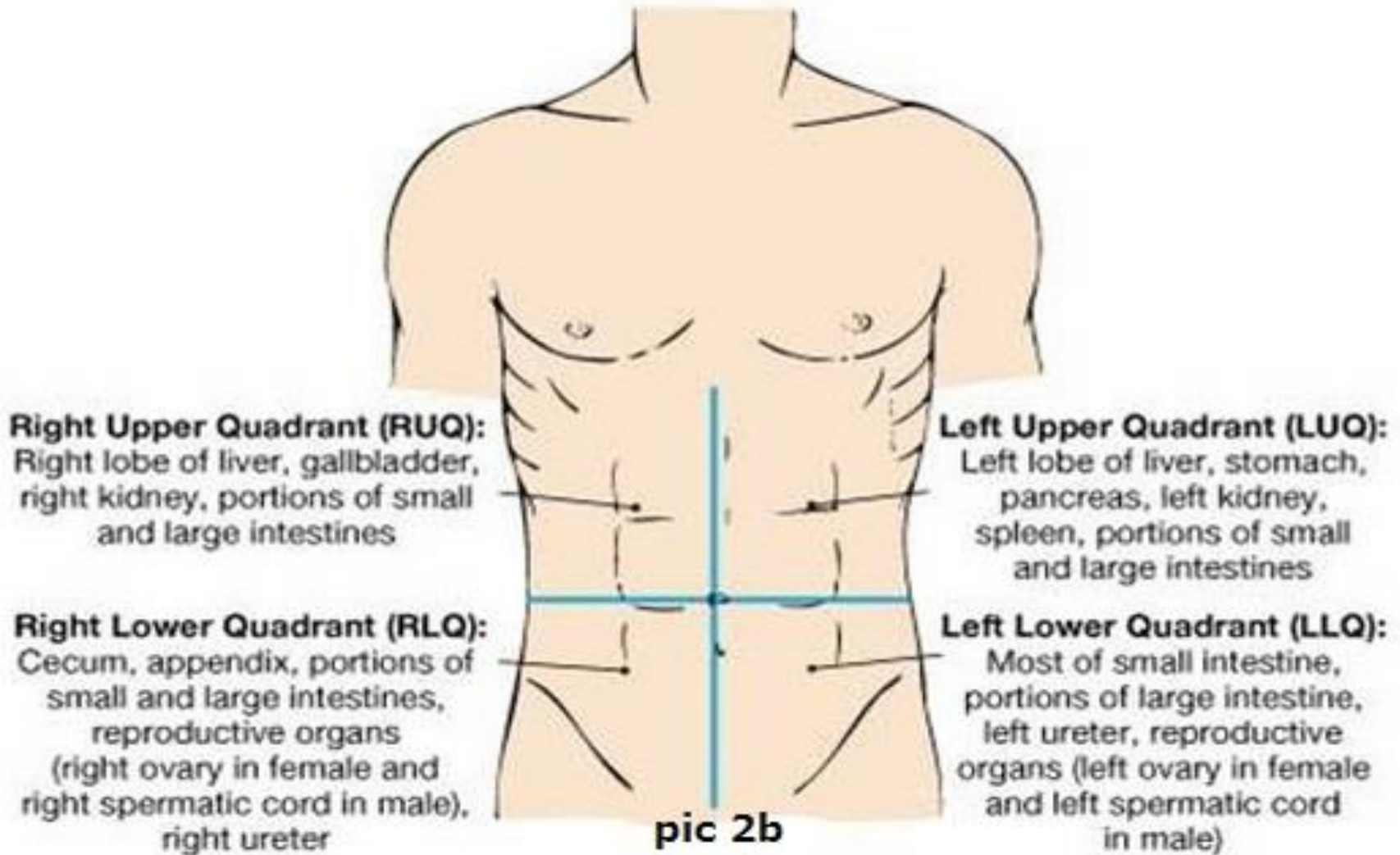


(a) Abdominopelvic regions



(b) Abdominopelvic quadrants

# Body Quadrants



# Body Cavities

